

Sir,
Foveal schisis with Mizuo phenomenon: Etiopathogenesis of tapetal reflex in X-linked retinoschisis
Mizuo phenomenon has been rarely reported in juvenile X-linked retinoschisis (XLR).¹ We report a case of XLR with peripheral Mizuo phenomenon² which presented as isolated foveal schisis.

Case report

A 16-year-old male presented with diminution of vision OS since 1 year. He had no history of nyctalopia. Best-corrected visual acuity was 6/9 OD and 6/24 OS. Colour vision was normal. Fundus evaluation showed dull foveal reflex and a tapetal reflex in the periphery. After 5 h of dark adaptation, the tapetal reflex disappeared (Mizuo phenomenon) (Figure 1), which

reappeared within a minute of light exposure. Full-field electroretinogram (Metrovision, France) showed reduction of 'b'-wave amplitude of combined maximal scotopic response and reduced cone ON–OFF responses (Figure 2). Optical Coherence Tomography (OCT) showed intraretinal foveal schisis (Figure 3).

Comment

Muller cells regulate extracellular K^+ ion concentration in the retina.³ In XIS, Muller cell dysfunction occurs secondary to the splitting of the nerve fibre layer. This causes defective inward transportation of K^+ ions from the inner and outer plexiform layers. The excess of extracellular K^+ ions causes Mizuo phenomenon.¹ But the fact that most patients with XLR do not demonstrate tapetal reflex is intriguing. The nonuniform distribution of K^+ channels across muller cell in retina⁴ and

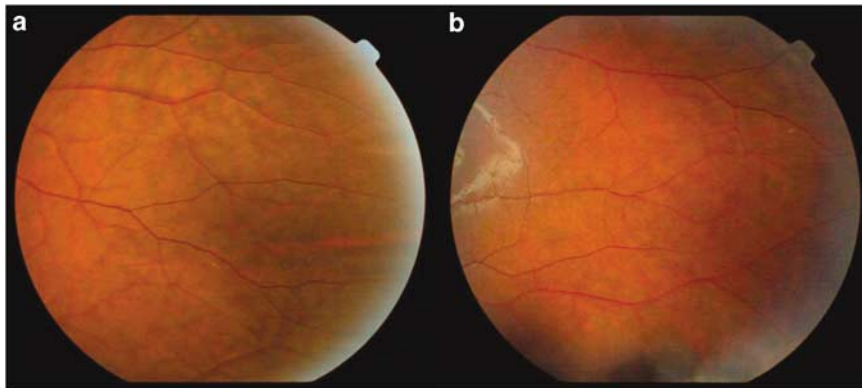


Figure 1 Fundus photograph of the left eye. (a) Tapetal reflex in the temporal periphery in the left eye. (b) Disappearance of the reflex following prolonged dark adaptation.

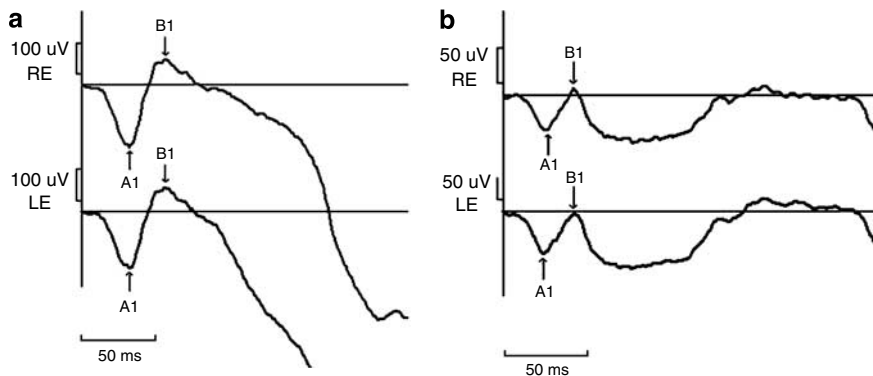


Figure 2 Full field electroretinography recordings. (a) Forty percentage reduction in 'b' wave amplitude of combined maximal scotopic response was noted in both eyes. (b) Reduced cone ON and OFF bipolar response in both eyes.

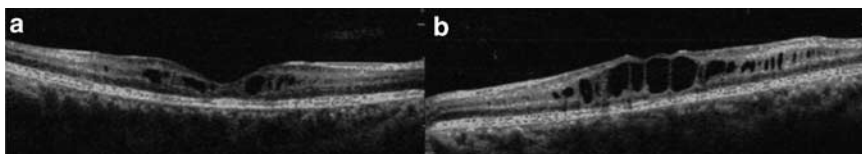


Figure 3 OCT from both eyes. (a) OCT from the right eye showing foveal schitic changes with macular atrophy. (b) OCT from the left eye shows intraretinal bridging columns in between hyporeflexive spaces classical of foveal schisis.

differential affection of muller cell segment in XLR are possible explanations. This suggests that if adequate numbers of K^+ channels are intact, the reflex is absent. As greater numbers of K^+ channels are affected, Mizuo phenomenon becomes demonstrable wherein excessive K^+ ions are cleared during dark adaptation. When most of the K^+ channels are affected, the tapetal reflex becomes constant, as there is persistent K^+ ion backlog. Previous reports of increased tapetal reflex with time¹ suggest progressive K^+ channel damage in XLR. Tapetal reflex disappeared following vitrectomy and posterior hyaloid peeling⁵ in XLR. The disruption of K^+ channels at muller cell foot plate during the surgical procedure could have increased the inward conductance of K^+ ions trapped within dysfunctional muller cells causing disappearance of the reflex. The selective reduction of 'b' wave of combined maximal ERG and foveal schisis on OCT confirmed diagnosis of XLR in the absence of peripheral retinoschisis and presence of Mizuo phenomenon.

References

- 1 Jong PTVM, Zrenner E, van Meel GJ, Keunen JE, van Norren D. Mizuo phenomenon in X-linked Retinoschisis. *Arch Ophthalmol* 1991; **109**: 1104–1108.
- 2 Mizuo G. A new discovery in dark adaptation in Oguchi's disease. *Acta Soc Ophthalmol Jpn* 1913; **17**: 1148–1150.
- 3 Newman EA. Membrane physiology of retinal glial (Muller) cells. *J Neurosci* 1985; **5**: 2225–2239.
- 4 Newman EA. Distribution of potassium conductance in mammalian Muller (glial) cells: A comparative study. *J Neurosci* 1987; **7**: 2423–2432.
- 5 Miyake Y, Terasaki H. Golden tapetal-like fundus reflex and posterior hyaloid in a patient with X-linked juvenile retinoschisis. *Retina* 1999; **19**: 84–86.

A Vincent, R Shetty, NK Yadav and BK Shetty

Department of Visual Electrophysiology and Vitreoretina, Narayana Nethralaya, Super Speciality Eye Hospital and Post Graduate Institute of Ophthalmology, Bangalore, Karnataka, India
E-mail: ajoytvincent@rediffmail.com

The authors have no proprietary interests in this report.

Eye advance online publication, 6 June 2008;
doi:10.1038/eye.2008.170